



PATIENT

Thor Almeida

SPECIES

Canine

BREED

Pomeranian

SEX

Male

AGE

9 years

WEIGHT

9.6lbs

INTERPRETED BY

Maggie Machen Lamy,
DVM, DACVIM
(Cardiology)

IMAGING PERFORMED BY

Shari Reffi, CVT

HOSPITAL NAME

All Creatures Great
and Small Denville

REFERRING VET

Dr. Mitrovic

INVOICE

25674

DATE

8/9/22

PRESENTING CLINICAL SIGNS

History: Recheck echo. Grade II-III/VI heart murmur. Occasional cough.
-Current medications: Pimobendan 1.25mg 1am, 1/2 pm; Lasix 12mg 1/2 bid; Enalapril 2.5 SID.
-Pertinent previous echo findings (9/2021 NJ Vet Cardio): CVD with moderate LAE and CHF. LA/AO: 1.6, LV; 3.0, TR: 2.7.

ECHOCARDIOGRAM FINDINGS

2D, m-mode, color flow and doppler imaging is available. Diffuse thickening of mitral valve leaflets with mild prolapse into the left atrial lumen. Severe eccentric mitral regurgitation with moderate left atrial dilation. Normal MR velocity. Minimal LV dilation with adequate myocardial function. The tricuspid valve appears normal, with mild TR. Normal velocity. Normal right atrial and ventricular diameter and morphology. The pulmonic and aortic valves are normal in morphology and mobility. Normal aortic and pulmonic outflow velocities with laminar flow. No AI/PI. No pericardial or pleural effusion noted. No obvious cardiac masses.

CARDIAC CHART

CANINE CARDIAC PARAMETERS	MR VMAX (m/s)	TR VMAX (m/s)	LA/AO (Boon method)	LA/AO (Heart Base; Swe)	FS (%)	EF (%)	EPSS (cm)
NORMAL PARAMETER	4.5-5.5	<2.7	1.3	<1.6	28-40	40-100	<0.6
PATIENT	5.5	2.7	1.8	1.7	39	71	0.24
CANINE CARDIAC PARAMETERS	HR (BPM)	AV VMAX (m/s)	PV MAX (m/s)	BODY WEIGHT (kg)	LA 2D short axis Base view (cm)	LVIDd Avg; 2D and m-mode short axis (cm)	LVIDs Avg; 2D and m-mode short axis (cm)
NORMAL PARAMETER	50-100	0.7-1.7	0.7-1.6	BELOW	BELOW	BELOW	BELOW
PATIENT	88	1.3	1.2	4.4	1.9	2.8	1.7
*Normal chamber parameters expressed as a mean value (SD)				3	1.27 (5.3)	2.46 (2.46)	1.36 (5.5)
BODY WEIGHT DEPENDENT PARAMETERS				5	1.40 (4.5)	2.74 (5.2)	1.60 (4.7)
<i>*Note: All measurements based upon multi-modal images and methods. An average value is reported.</i>				10	1.50 (3.8)	3.27 (3.5)	2.06 (3.1)
				15	1.83 (2.0)	3.71 (2.4)	2.43 (2.1)
				20	2.02 (1.9)	4.14 (2.2)	2.80 (2.0)
				25	2.18 (2.4)	4.48 (2.9)	3.10 (2.5)
				30	2.33 (3.3)	4.83 (3.9)	3.39 (3.4)
				35	2.48 (4.3)	5.17 (5.0)	3.69 (4.5)
				40	2.62 (5.2)	5.48 (6.1)	3.96 (5.4)
				50	2.88 (7.1)	6.07 (8.3)	4.46 (7.4)

INTERPRETATION OF THE FINDINGS & FURTHER RECOMMENDATIONS

The cause of the murmur is chronic degenerative valve disease causing severe mitral and mild tricuspid regurgitation. Moderate left atrial enlargement indicates the risk for complication is relatively low. Compared to what is available from the prior study, findings are similar without obvious progressive volume overload. No additional issues are identified.

While it is uncommon for moderate disease to lead to pulmonary edema, this is noted on the prior report. Based upon these findings, continued cardiac support is recommended lifelong with addition of Spironolactone. Monitoring of sleeping respiratory rates will be paramount to screen



PATIENT

Thor Almeida

SPECIES

Canine

BREED

Pomeranian

SEX

Male

AGE

9 years

WEIGHT

9.6lbs

INTERPRETED BY

Maggie Machen Lamy,
DVM, DACVIM
(Cardiology)

IMAGING PERFORMED BY

Shari Reffi, CVT

HOSPITAL NAME

All Creatures Great
and Small Denville

REFERRING VET

Dr. Mitrovic

INVOICE

25674

DATE

8/9/22

for congestive heart failure at home. Cough suppression to improve QOL can also be considered (hydrocodone, 0.2-0.4mg/kg up to q4-6h PRN) for any residual mechanical cough in the face of normal sleeping respiratory rates. The average survival time of canine patients with active pulmonary edema is 8-9 months on medications, however they generally are able to maintain a good quality of life for that period. Patient will always be at risk for recurrent CHF, development of arrhythmias/LA tear, syncope and/or sudden death in the future.

Omega fatty acid supplementation and mild salt restriction may also be of some long-term benefit. Monitor for acute progression of the cough, labored breathing, exercise intolerance or collapse episodes in the future.

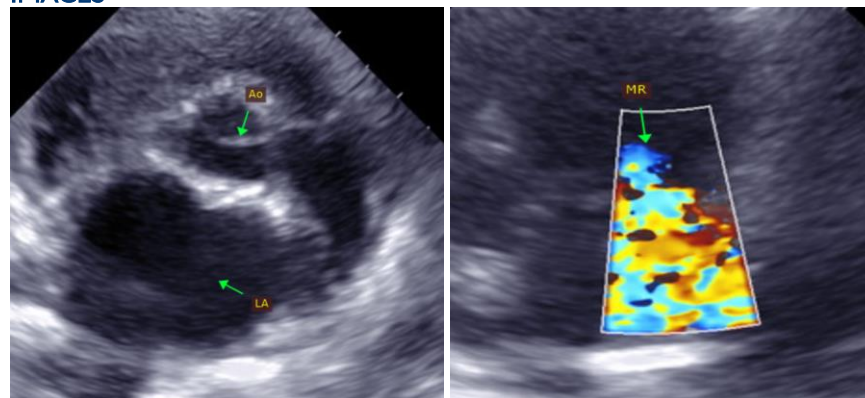
PLAN

Continue Pimobendan, Lasix and Enalapril as prescribed. Institute Spironolactone 1-2mg/kg PO q12h.

Monitor SRRs at home. Monitor renal values and BP every 3-4 months lifelong.

Recommend conservative monitoring with a recheck echocardiogram in 6 months, sooner if any development of associated clinical signs occurs in the interim.

IMAGES



The information and recommendations provided are based on the images presented by the referring veterinarian. No evaluation can be communicated regarding pathology that was not visible in the image/video clips provided.

Thank you for this referral. This report was generated using transcription software, and minor dictation errors may be present. If the clinical or image interpretation does not parallel your findings or if I can be of any further assistance, please contact me.

Maggie Machen Lamy, DVM
Diplomate of the American College of Veterinary Internal Medicine (Cardiology)
info@sonopath.com